

Breast Reconstruction Using Perforator Flaps

Case Examples

Frederick J. Duffy, Jr., M.D., F.A.C.S

Click anywhere on screen to go to next slide or click on arrows below.

Case Examples

The following patients are actual patients of mine. Additional examples are available in the office for patients to review.

It is important for each patient to realize that their results may vary.

We are very grateful to these patients for allowing us to use their photographs in this presentation.

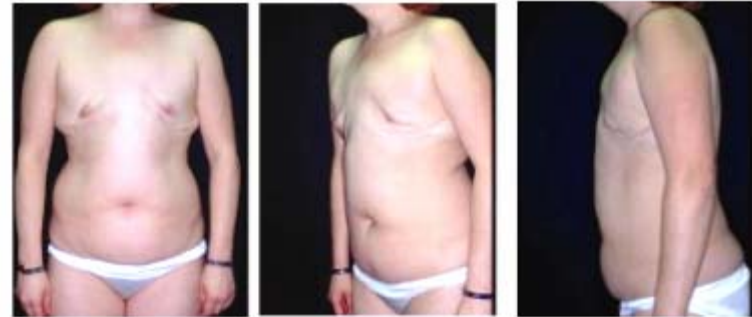Click anywhere on screen to go to next slide or click on arrows below.

DIEP Flap

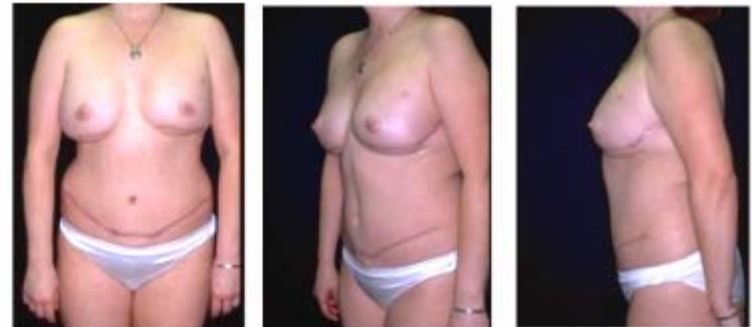This patient had previously had bilateral mastectomies for fibrocystic disease, followed by reconstruction with implants, done by another surgeon. She had multiple sets of implants done elsewhere, with complications ultimately requiring removal of the implants prior to her coming to my office for the first time.

In addition, she had multiple allergies including to various types of mesh which are often used to reconstruct the abdominal wall following a traditional TRAM flap. Because of this, she was an ideal candidate for a DIEP flap. She has an excellent early result with a nicely recontoured abdomen and full, soft breasts.

Preoperative



Postoperative

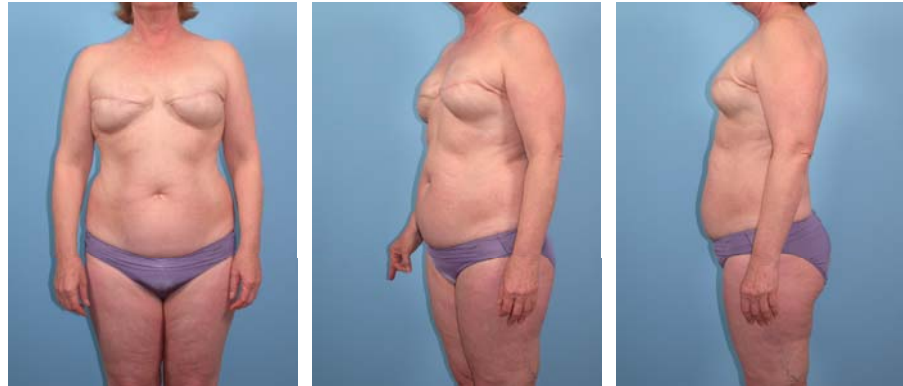


Click anywhere on screen to go to next slide or click on arrows below.

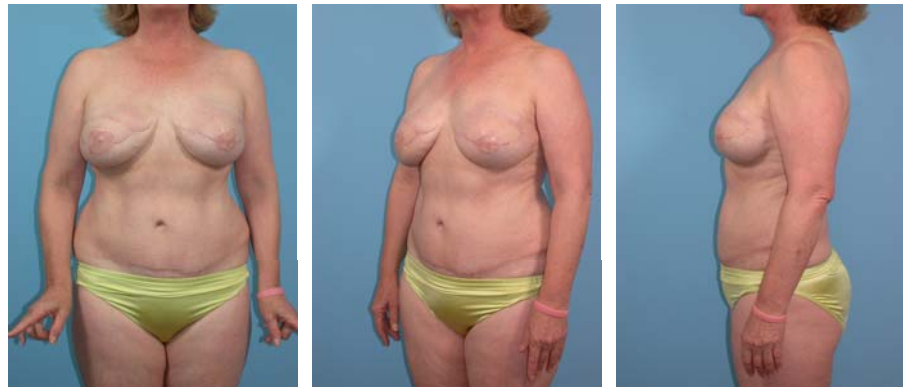DIEP / SIEA Flap

This patient had undergone bilateral prophylactic mastectomies due to an extensive family history of breast cancer and multiple previous biopsies. Her first reconstruction, done elsewhere, was with silicone implants. The patient was unhappy with the results and was having some pain in the left breast. The implants were removed and she had an SIEA flap on the right side and a DIEP flap on the left side.

Preoperative



1 Year Postoperative

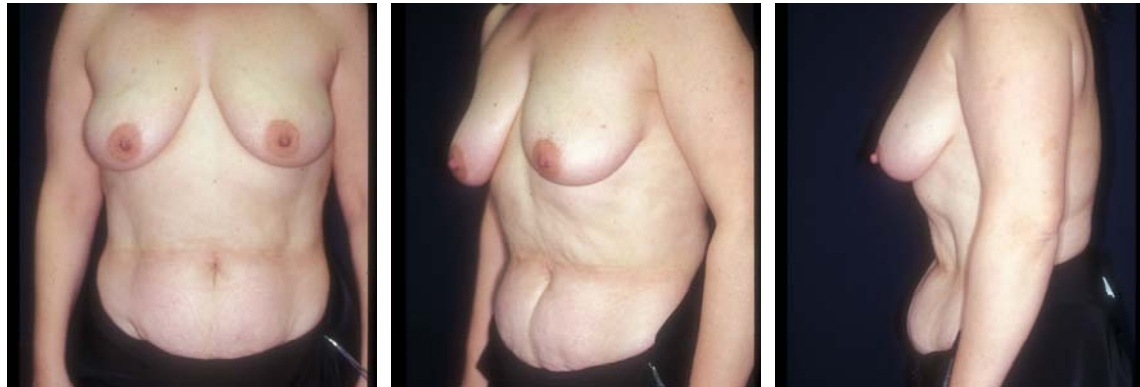

Click anywhere on screen to go to next slide or click on arrows below.

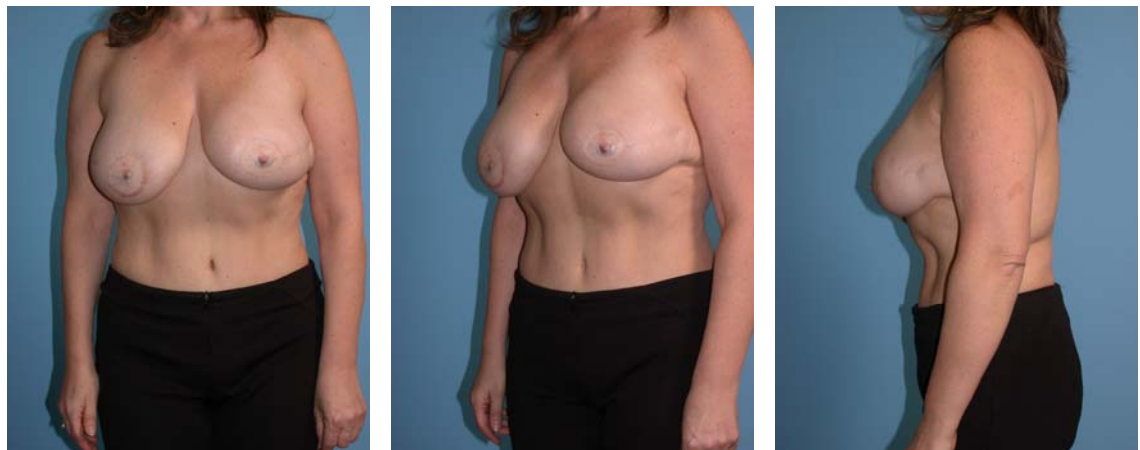
DIEP Flap

This patient was diagnosed with left breast cancer and dysplasia of the right breast so she presented for bilateral mastectomies by her breast surgeon and immediate reconstruction by Dr. Duffy with DIEP flaps. Seven months after the surgery she had a revision procedure with nipple/areolar reconstruction.

Preoperative



4 Years Postoperative



Close this window to return to the website.